

Isolated Tuberculous Osteomyelitis of Toe: A Case Report

Veena P. Waiker*

Udayashankar**

*Professor, Department of Plastic Surgery, M.S. Ramaiah Hospital, Bangalore.

**Professor, Department of Plastic Surgery, M.S. Ramaiah Hospital, Bangalore.

Accepted on 06.12.2012

Abstract

Isolated extra pulmonary tuberculous osteomyelitis of the phalanx is rare as compared to that of proximal bones. We report a case of tubercular osteomyelitis of the middle phalanx of the toe in a 74 year old lady, presenting as post traumatic chronic ulcer which is even more rare. The difficulty in diagnosis and the related problems, the need to have a high index of suspicion of tuberculosis as one of the causes of chronic foot ulcer especially in developing countries has been emphasized.

Key-words: Tuberculosis; Osteomyelitis; Phalanx; Toe.

Introduction

Skeletal tuberculous osteomyelitis has been described, but involvement of the bones of hands and feet is rare while that of phalanx of the toe presenting as post traumatic non healing ulcer is very rare. There are very few reports regarding isolated involvement of phalanges [1,2]. It is a major health concern in developing countries even today. The increased incidence of immune-suppression due to various reasons has again led to the rise in tuberculosis.[3]

Musculoskeletal involvement may occur along with pulmonary lesion or as a delayed primary extra pulmonary lesion after many years. The chances of missing the diagnosis and progress of the disease are high in chronic ulcer. We hereby present a rare and isolated case of tuberculous osteomyelitis of toe which came to notice following a trivial injury.

Case presentation

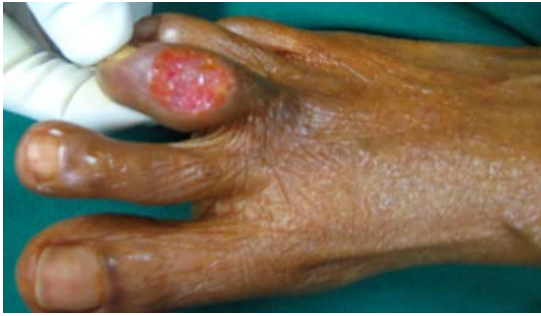A 74 year old lady presented to our hospital with chronic non healing ulcer of one year duration, on the third toe of her right foot following trivial trauma. She complained of pain, discharge and swelling of the toe which was treated conservatively with dressings and analgesics. Intermittent courses of antibiotics

Corresponding Author:

Dr. Veena P. Waiker, 19 F-1, Vinayaka layouts 3rd Stage ,
Vijayanagar, Bangalore-560040. Mob. No. 9900531217.

E-mail : veenaprabhakar2003@yahoo.com

Fig 1: Chronic non healing ulcer dorsum of third toe – right foot

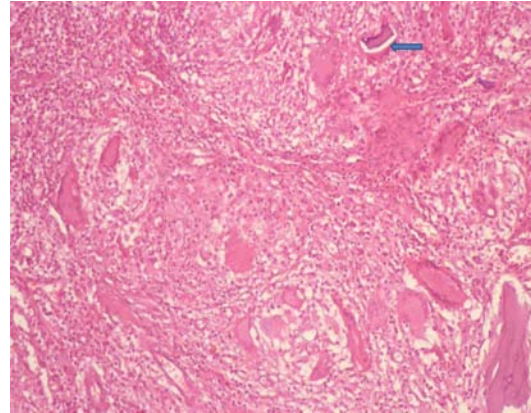


were administered based on culture and sensitivity reports by her family physician. There was no history of fever but she had loss of appetite and loss of about 3 kgs of weight in a period of six months. Physical examination revealed an ulcer of 1cm diameter overlying the dorsum of third toe of her right foot. (Fig 1) Interphalangeal joint movements were restricted and painful. There was surrounding oedema. Dorsalis pedis and posterior tibial artery pulsations were well felt bilaterally. There was no regional lymphadenopathy. The chest and abdomen were clinically normal. Plain radiograph of right foot which was done one month after trauma was found to be normal. Six months later it revealed cortical erosion of middle phalanx of third toe with osteoporosis of distal and proximal phalanges. (Fig 2) A diagnosis of post traumatic non healing ulcer due to chronic osteomyelitis was

Fig 2: X-ray showing cortical erosion of middle phalanx

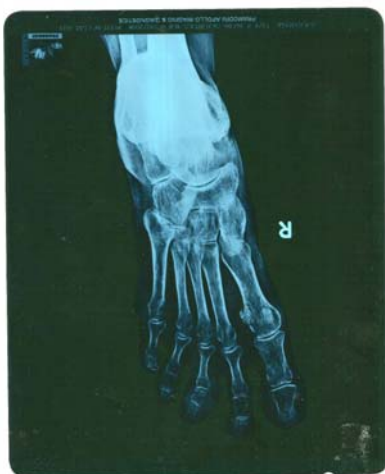

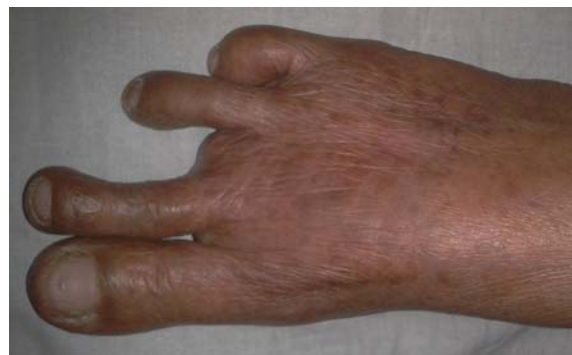Fig 3: Histopathology (High power) showing confluent tuberculous granulomas composed of epithelioid cells, Langhans giant cells and lymphocytes. A spicule of bone is seen (arrow)



made having Marjolin's ulcer as differential diagnosis. On admission Haemoglobin was 11.1gms%, Random blood sugar 104.4 mg/dL and E.S.R. 8mm/hour. Chest roentgenogram was normal.

The involved toe was disarticulated at the metatarsophalangeal joint and closed with Fillet flaps. The specimen of bone and soft tissue was found to be infiltrated with granulomas composed of epithelioid cells, multinucleated giant cells and lymphocytes without caseous foci on histopathological examination which suggested tuberculous osteomyelitis. (Fig3) Bacteriological examination did not reveal any growth on culture and subsequent ZN stain was negative for AFB. The wound healed in a weeks' time. (Fig 4) Patient was treated with four drugs Rifampicin, Isoniazid, Ethambutol

Fig 4: 5 years later – well settled scar



and Pyrazinamide from the tenth post-operative day for two months followed by two drugs Isoniazid and Rifampicin in combination with Pyridoxine for another four months after prior liver function tests and ultrasound abdomen which were normal. Her appetite improved and she regained 4 kgs of weight in five months.

Discussion

Extra pulmonary skeletal tuberculosis comprises of 1 to 5 percent of all tuberculous infections and usually occurs due to lympho haematogenous spread from lungs [4]. It may also affect otherwise healthy individuals. Long bones are less commonly involved compared to vertebral bodies due to the sluggish circulation. Tuberculous osteomyelitis of metatarsal bones and phalanges are rare but has been reported [5] whereas there are no reports on tuberculous osteomyelitis of phalanx presenting as post traumatic non healing ulcer. The common clinical symptoms are localised pain, swelling and discharge like in our patient. Occasionally it may be accompanied by constitutional symptoms such as fever and weight loss. Diagnosis of tuberculous osteomyelitis is usually delayed because the signs and symptoms are subtle [6]. The delay in diagnosis and administration of anti-tubercular drugs resulted in progress of the disease leading to loss of the toe in our patient. Laboratory tests, like erythrocyte sedimentation rate, complete blood count and fine needle aspiration may not be conclusive. Radiological changes on plain X-ray are not seen initially. However, typical radiological appearances like osteolytic areas with osteoporosis and periosteitis on x ray is difficult to differentiate from chronic pyogenic osteomyelitis and tumours. An MRI scan is more sensitive in localising the lesion in the early stages [7] but has to be confirmed by an open biopsy.

Histopathological diagnosis was an incidental diagnosis in our patient, as the surgical specimen was sent for histopathology with Marjolin's ulcer and chronic pyogenic

osteomyelitis as differential diagnosis. Subsequent Zeil Neilson staining was done to confirm the histopathology report but did not reveal AFB. The diagnosis is said to be more accurate with histopathology of the specimen and PCR [8]. AFB may be absent on stain and culture as tuberculous osteomyelitis is usually paucibacillary [9]. Hence, histopathological diagnosis in correlation with clinical and radiological findings prompted anti-tubercular therapy and healing of the surgical wounds with cure of the disease in our patient. Tuberculosis still remains a major health problem in developing countries despite the advances in anti-tuberculous drugs. In fact, the incidence of tuberculosis has risen again, which is probably associated with increase in incidence of diabetes [10], viral fever, HIV, increasing number of patients on immunosuppressive agents and emergence of drug resistant strains of mycobacterium.

Hence, we recommend the clinicians especially in developing countries to have a high index of suspicion and do an open biopsy for bacteriological and histological examination in chronic ulcers not responding to antibiotics and analgesics in otherwise healthy individuals. This helps in detecting asymptomatic cases, early diagnosis and timely administration of anti-tuberculous drugs which along with the required surgical procedure aids in wound healing and resolution of the disease.

References

1. Mandeep S Dhillon, Sameer Aggarwal, Sharad Prabhakar, Vikas Bachhal. Tuberculosis of the foot. An Osteolytic variety. *Indian J Orthop.* 2012; 46(2): 206-211.
2. Rajeev Vohra, Harinder S Kang, Sameer Dogra, Radha R Sagar, Rajan Sharma. Tuberculous Osteomyelitis. *J Bone Joint Surg [Br]*. 1997; 79-B: 562-6.
3. Davies PD. The world-wide increase in tuberculosis: how demographic changes, HIV infection and increasing numbers in poverty are

- increasing tuberculosis. *Ann Med.* 2003; 35(4): 235-43.
4. MC Yuen, WK Tung. An uncommon cause of foot ulcer: tuberculous osteomyelitis. *Emerg Med J.* 2001; 18(2): 140-141.
 5. Kushwaha RA, Kant S, Verma SK, Sanjay, Mehra S. Isolated metacarpal bone tuberculosis-a case report. *Lung India.* 2008; 25(1): 17-9.
 6. Choi WJ, Han SH, Joo JH, Kim BS, Lee JW. Diagnostic dilemma of tuberculosis in the foot and ankle. *Foot Ankle Int.* 2008; 29(7): 711-5.
 7. MC Yuen, WK Tung. An uncommon cause of foot ulcer: tuberculous osteomyelitis. *Emerg Med J.* 2001; 18: 140-141.
 8. Margaret D, Phillips MD. Presented by Stephen J Pomeranz, M.D. The MRI Mentor TM New Research and Trends in Advanced Imaging. 2011; 5(3).
 8. Anil K Jain, Santosh Kumar Jena, MP Singh, IK Dhammi, VG Ramachadran, Geeta Dev. Evaluation of clinico-radiological, bacteriological, serological, molecular and histological diagnosis of osteoarticular tuberculosis. *Indian J Orthop.* 2008; 42(2): 173-177.
 9. Shanmugasundaram TK. Bone and joint tuberculosis-Guidelines to management. *Indian J Orthop.* 2005; 39(3): 195-198.
 10. Jeremy D Goldhaber-Fiebert, Christie Y Jeon, Ted Cohen, Megan B Murray. Diabetes Mellitus and Tuberculosis in countries with high Tuberculosis Burdens: Individual risks and Social Determinants. *Int J Epidemiol.* 2011; 40(2): 417-428.